

An alternative method for the treatment of nonunion of the tibia with bone loss

C. Sen,
L. Eralp,
T. Gunes,
M. Erdem,
V. E. Ozden,
M. Kocaoglu

From
Gaziosmanpasa
University, Tokat,
Turkey

In this retrospective study we evaluated the method of acute shortening and distraction osteogenesis for the treatment of tibial nonunion with bone loss in 17 patients with a mean age of 36 years (10 to 58). The mean bone loss was 5.6 cm (3 to 10). In infected cases, we performed the treatment in two stages. The mean follow-up time was 43.5 months (24 to 96). The mean time in external fixation was 8.0 months (4 to 13) and the mean external fixator index was 1.4 months/cm (1.1 to 1.8). There was no recurrence of infection. The bone evaluation results were excellent in 16 patients and good in one, while functional results were excellent in 15 and good in two. The complication rate was 1.2 per patient.

We conclude that acute shortening and distraction osteogenesis is a safe, reliable and successful method for the treatment of tibial nonunion with bone loss, with a shorter period of treatment and lower rate of complication.

The treatment of nonunion of the tibia with associated bone loss can be difficult. Such bone loss is often the result of failed operative treatment and may be accompanied by chronic infection. Reconstruction is particularly challenging in patients with deformity, soft-tissue loss, and leg-length discrepancy. Several methods of treatment have been described including the Papineau technique,¹ vascularised or non-vascularised transfer of the fibula, debridement and resection of bone followed by vascularised muscle transfer and bone grafting, bone grafting followed by internal fixation, and electrical stimulation.¹⁻⁷ However, these methods may not correct deformity and leg-length discrepancy. Treatment is often long and complications frequent. High rates of nonunion and recurrence of infection have been reported. Recently, the introduction of the distraction osteogenesis and bone transport technique of Ilizarov⁸ has allowed problems of infection, shortening, deformity, soft-tissue loss, and joint contracture to be addressed.^{7,9-21} Based on the Ilizarov philosophy, tibial nonunion with bone loss can be managed by acute shortening after resection at the site of the nonunion combined with lengthening of the shortened bone at another level. Our aim was to evaluate the results of our experience with this technique in patients with tibial nonunion and bone loss.

Patients and Methods

Our study was retrospective and was based on clinical and radiological assessment. Between July 1997 and July 2003, 17 patients (16 male, 1 female) with atrophic tibial nonunion were treated surgically in our two departments by acute shortening and resection followed by distraction osteogenesis. Their mean age at operation was 36 years (10 to 58). The mean number of previous operations was 3.1 (1 to 8). The total bone loss was calculated as the previous bone defect plus the amount resected at surgery. The mean total bone loss was 5.6 cm (3 to 10). According to the classification of Paley et al⁹ bone loss was type B1 in three patients, type B2 in eight and type B3 in six. There were ten patients who had a soft-tissue defect with a mean size of 2 x 2.5 cm (1 x 1 to 5 x 8) on the anteromedial or anterolateral aspect of the tibia. Of the 17 patients, 11 were infected at the time of reconstruction. These were classified as type IIIB in two, type IVA in five, and type IVB in four according to the classification of Cierny, Mader and Penninck.²² CT was used in all patients to decide on the amount of resection of dead and/or infected bone. We also performed angiography to establish the vascular status of the involved limb because all patients had previously had surgery. Details of the 17 patients are given in Table I.

In infected cases, treatment was performed in two stages. In the first stage, radical resec-

■ C. Sen, MD, Orthopaedic Surgeon, Associate Professor
■ T. Gunes, MD, Orthopaedic Surgeon, Assistant Professor
■ M. Erdem, MD, Orthopaedic Surgeon, Assistant Professor
Department of Orthopaedics and Traumatology
Medical School of
Gaziosmanpasa University,
Tokat, Turkey

■ L. Eralp, MD, Orthopaedic Surgeon, Associate Professor
■ V. E. Ozden, MD, Orthopaedic Surgeon
■ M. Kocaoglu, MD,
Orthopaedic Surgeon,
Professor
Department of Orthopaedics and Traumatology
Medical Faculty of Istanbul
University, Istanbul, Turkey.

Correspondence should be sent to Dr C. Sen; e-mail: senc64@yahoo.com

©2006 British Editorial Society of Bone and Joint Surgery
doi:10.1302/0301-620X.88B6.17515 \$2.00

J Bone Joint Surg [Br]
2006;88-B:783-9.

Received 7 December 2005;
Accepted after revision
22 February 2006

Table I. Clinical details of the 17 patients

Case	Age (yrs)	Gender	Number of previous operations	Cierny-Mader type ²²	Additional treatment	Follow-up (mths)	Bone loss (cm)	External fixator time (mths)	Bone healing time (mths)	Current bone status		Current functional status	
										Union	Results	Situation of joints ^a	Results
1	53	M	1	IVB		29	7	10	11	Union	Excellent	Full ROM	Excellent
2	48	M	1	IVB		27	6	10	10	Union	Excellent	Full ROM	Excellent
3	33	F	3			64	3	4	5	Union	Excellent	Full ROM	Excellent
4	43	M	4			96	5	8	7	Union	Excellent	Full ROM	Excellent
5	24	M	1	IVA		25	4	7	8	Union	Excellent	Full ROM	Excellent
6	33	M	2	IVA		36	7	10	11	Union	Excellent	Full ROM	Excellent
7	22	M	2	IVA		24	8	12	13	Union	Excellent	Full ROM	Excellent
8	26	M	5	IIIB	Bone graft	58	4	7	8	Union	Excellent	Full ROM (brace required)	Good
9	45	M	1			34	3	5	5	Union	Excellent	Full ROM	Excellent
10	35	M	3			32	4	6	7	Union	Excellent	Full ROM	Excellent
11	26	M	3			72	3	5	6	Union	Excellent	Full ROM	Excellent
12	58	M	1			74	3	5	6	Union	Excellent	Full ROM	Excellent
13	55	M	6	IIIB	Bone graft	28	8	10	12	Union, 10° recurvatum	Good	Full ROM	Excellent
14	43	M	7	IVB	Bone graft	60	10	11	12	Union	Excellent	Full ROM	Excellent
15	18	M	8	IVA	Bone graft	32	5	7	8	Union	Excellent	Full ROM	Excellent
16	10	M	3	IVA		24	5	6	6	Union	Excellent	Full ROM	Excellent
17	43	M	2	IVB		24	10	13	14	Union	Excellent	10° knee flexion contracture	Good

* ROM, range of movement

tion of dead bone with debridement of infected soft tissue was performed and cultures taken. These were positive in seven patients, with methicillin-resistant *Staphylococcus aureus* found in five and *Pseudomonas aeruginosa* in two. Patients with positive cultures were treated with antibiotics according to the culture and sensitivities for a minimum of six weeks or until the level of the erythrocyte sedimentation rate (ESR) and C-reactive protein (CRP) had returned to normal. After bone and soft-tissue resection, custom-made antibiotic beads (a combination of teicoplanin (2.4 g) and polymethylmethacrylate (40 g)) were placed in the dead space (Fig. 1). Immobilisation was provided by a temporary external fixator in seven patients and a custom-made brace in four (Figs 1d and 1e). The remaining six patients were treated with an antibiotic (first-generation, cephalosporin) given 30 minutes before and for two days after operation.

When the levels of the ESR and CRP had returned to normal the patients underwent final surgery. After removal of the antibiotic beads a biopsy was taken from the bone gap and sent for Gram staining (Demirkapi, Istanbul, Turkey) and frozen-section analysis. If no micro-organisms were detected by Gram staining and there was a cut-off point of less than 3 to 4 polymorphonuclear leukocytes per high-power field, the infection was considered to be cured. This was achieved in all patients. Following this the patients all underwent second-stage surgery.

Operative technique. A transverse incision was used for the main procedure. Resection of the devitalised bone ends was followed by debridement and irrigation of the wound area with physiological saline. If the fibula was intact, a resection of the same length was performed at the same level. Before applying the external fixator, the leg was re-prepared

and the surgical team re-gowned and gloved. A preconstructed frame (Tasarim Medical, Istanbul, Turkey) was used. It usually consisted of four rings. A proximal reference wire was fixed and tensioned to the most proximal ring. Then a distal reference wire was fixed just proximal to the ankle. After fixation of bone ends with two wires, the alignment of the tibia was checked radiologically. If the tibia had normal alignment and orientation, acute shortening of up to 4 cm was performed. The amount of acute shortening was limited by the circulatory status of the foot. We assessed the viability of the foot by palpation of the dorsalis pedis and posterior tibial pulses, assessment of capillary refill, Doppler ultrasound and measurement of the oxygen saturation of the hallux. If there was interference with circulation after shortening, the tibia was re-lengthened until the circulation returned to normal. The remaining external fixation wires and half pins were then inserted. If the resection gap was close to the ankle the foot was incorporated into the frame to prevent an equinus contracture and to enhance stability. Finally, distraction osteotomy was performed either using a Gigli saw (Tasarim Medical) or by multiple drill holes and corticotomy. In our experience, acute shortening of up to 4 cm can be achieved safely. In patients with bone defects of more than 4 cm, acute shortening of 4 cm was followed by gradual shortening of 2 mm/day post-operatively (Figs 1f and 1g).

Patients began daily physiotherapy the day after surgery and wore custom-made shoes with dorsiflexion straps to prevent an equinus contracture. They were encouraged to bear weight partially with crutches on the second day after surgery. Full weight-bearing was allowed at the end of the distraction period. Thromboprophylaxis was not used in

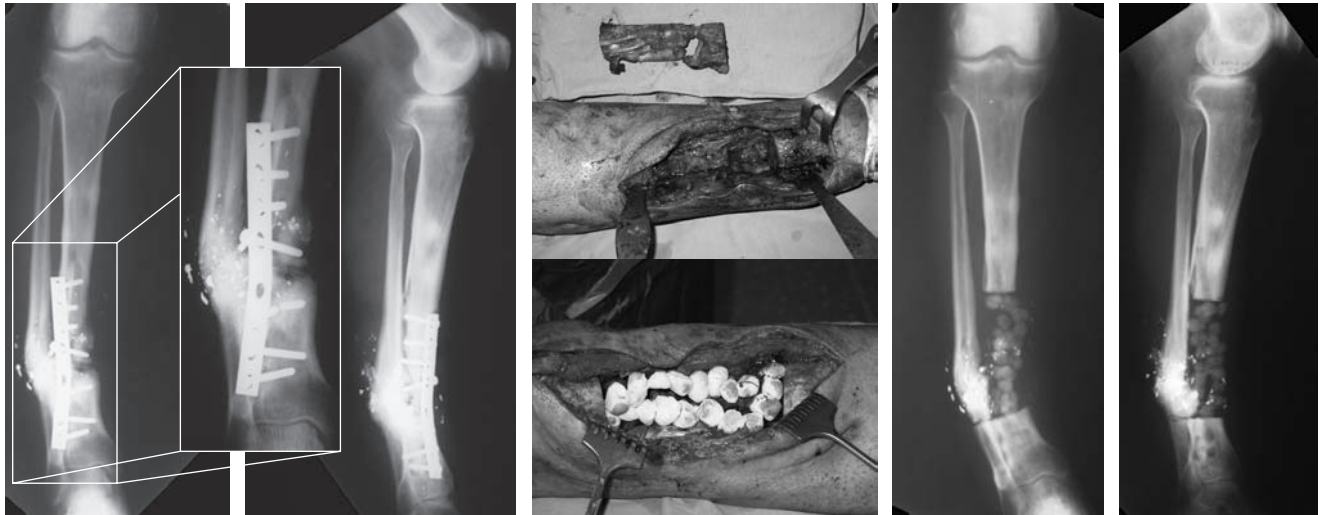

Fig. 1a

Fig. 1b

Fig. 1c

Fig. 1d

Fig. 1e

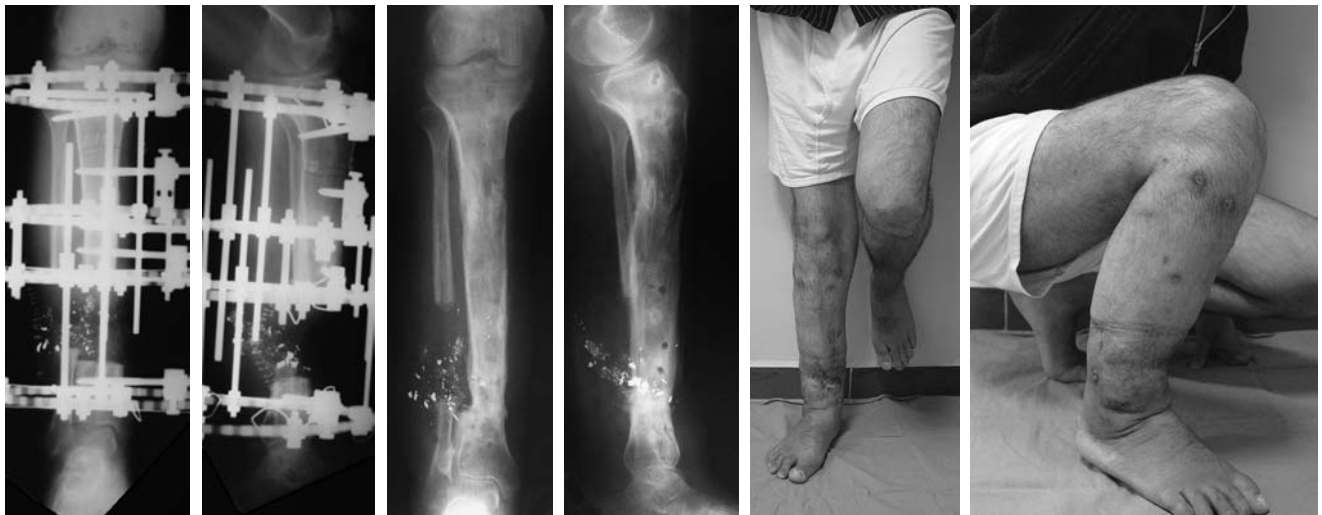

Fig. 1f

Fig. 1g

Fig. 1h

Fig. 1i

Fig. 1j

Fig. 1k

Case 14. A 43-year-old man who had undergone seven previous operations. Figures 1a and 1b – Radiographs showing pre-operative anteroposterior (AP) and lateral views. Figure 1c – Photographs showing intra-operative views in the first stage. Figures 1d and e – Radiographs showing early post-operative AP and lateral views after the first stage, f) and g) after the second stage and h) and i) at the last follow-up five years later. Figures 1j and 1k – Photographs showing the clinical appearance at the last follow-up.

any patient. Non-steroidal anti-inflammatory and/or narcotic analgesic medication was not used.

Distraction for lengthening was initiated at a quarter turn four times per day after a latency period of seven days. After docking was observed radiologically, the docking site was compressed by 0.25 mm per day to provide full contact between the bone ends until the patient complained of pain at the docking site. In the ten patients with soft-tissue defects, six were closed primarily after acute shortening and four had delayed primary closure at the end of gradual shortening.

Systemic oral ciprofloxacin (750 mg, twice daily) was prescribed for the patients who developed pin-track infection. Daily cleaning with Betadine solution (Merkez Labora-

tory, Istanbul, Turkey) and pressure was used for the care of the pin sites during the period of distraction.

If progress to union was not observed after three months, the docking site was re-opened and grafted. After removal of the external fixator, the leg was protected in a long-leg brace for four weeks with the patient bearing weight partially, after which full weight-bearing was allowed (Figs 1h to 1k).

Results

The mean follow-up period was 43.5 months (24 to 96) and the mean hospital stay was 6 days (3 to 9). The mean bone healing time was 8.8 months (5 to 14) and the mean

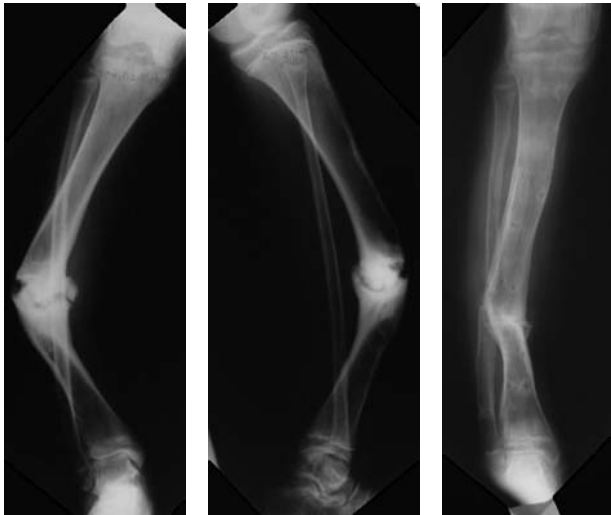


Fig. 2a

Fig. 2b

Fig. 2c

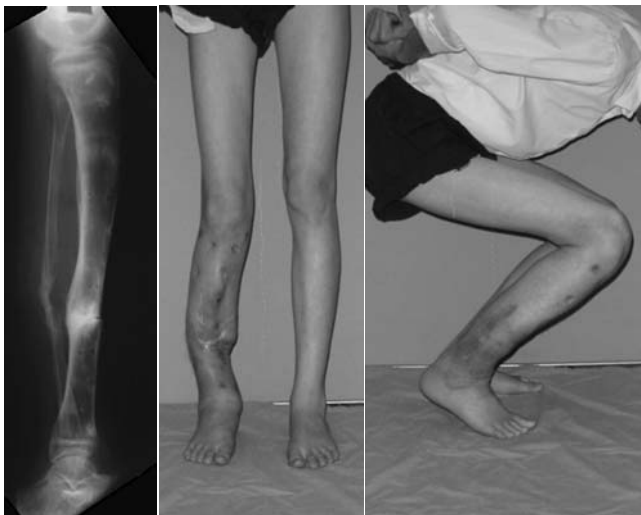

Fig. 2d

Fig. 2e

Fig. 2f

Case 15. An 18-year-old man who had undergone eight previous operations. Figures 2a and 2b – Radiographs showing anteroposterior and lateral views pre-operatively, and c) and d) after removal of the frame. Figures 2e and 2f – Photographs of the clinical appearance at the last follow-up, 32 months later.

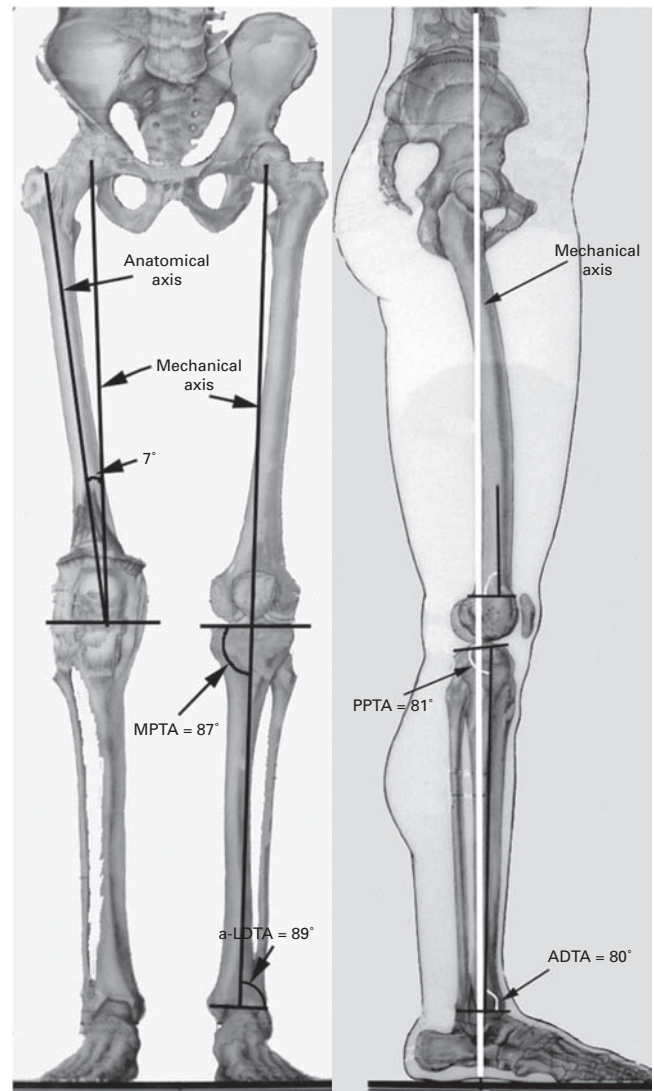


Fig. 3a

Fig. 3b

Radiological measurements in the a) frontal and b) sagittal planes. (MPPTA, medial proximal tibial angle; PPTA, posterior proximal tibial angle; LDTA, lateral distal tibial angle; ADTA, anterior distal tibial angle.)

external fixation time was 8.0 months (4 to 13). The mean external fixator index (EFI)^{10-16,18,19,21} was 1.4 months/cm (1.1 to 1.8). Complete union was obtained in all patients. No refractures occurred after removal of the frame. However, four patients required bone grafting at the docking site to obtain union. In the ten patients with a soft-tissue defect, acute or gradual compression at the docking site allowed primary or delayed primary closure without any secondary reconstructive procedure.

Control of infection was monitored in the clinic by clinical screening for local signs and symptoms and measuring the level of the ESR and CRP. No recurrence of infection was observed.

The bone and functional results were evaluated by the classification of Paley et al.⁹ Bone results were based on the state of union, the presence of infection, deformity, leg-length discrepancy and mechanical problems at the docking and regenerate sites. Functional results were assessed with regard to pain, walking without aids, contracture of the foot, ankle and knee, limitation of range of movement (ROM) of the knee, ankle and subtalar joints and the ability to return to normal daily activities and/or work.

We obtained excellent results in 16 patients (Fig. 2) and a good result in one in terms of bone assessment. The functional results were excellent in 15 patients, and good in two.

Table II. Details of the complications encountered

Complications	Number of complications	Number of patients	Complication rate (%)
Problems (minor complication)			
Grade-II pin-track infection	6	6	30
Translation/angulation at regenerate site	1	1	5
Delayed maturation of regenerate site	1	1	5
Transient loss of knee movement	1	1	5
Transient loss of ankle movement	1	1	5
Total	10		50
Obstacles (major complication)			
Grade-III pin-track infection	2	2	10
Soft-tissue invagination	1	1	5
Bone grafting	4	4	20
Equinus deformity	1	1	5
Total	8		40
Sequelae (true complication)			
Malalignment > 5°	1	1	5
Knee contracture > 5°	1	1	5
Total	2		10
Overall total	20		100

Radiographs were taken every two weeks during the distraction period and once a month during the consolidation phase. The results were evaluated on both anteroposterior and lateral radiographs. We measured the medial proximal tibial angle, the posterior proximal tibial angle, the lateral distal tibial angle, and the anterior distal tibial angle according to Paley et al²³ (Fig. 3). All radiographic measurements showed normal alignment and orientation at the last follow-up except in one patient (case 13), who had union with recurvatum of 10° (Table I).

Complications. A total of ten patients who required lengthening of more than 4 cm complained of pain during distraction. This was treated with analgesia (acetaminophen-codeine combination) as necessary. No neurovascular problems were caused either by intra-operative pin insertion or acute shortening. No patient developed compartment syndrome.

Complications were classified as minor (problems) which did not require additional surgery, major (obstacles) which resolved with additional surgery, and true complications (sequelae) which remained unresolved at the end of the period of treatment.²⁴

The most common complication was pin-track infection, which occurred in 20 of a total of 170 pin sites. According to Paley,²⁴ there were 12 grade-1 soft-tissue inflammations treated by local measures using Betadine solution (Merkez Laboratory) and oral antibiotics with resolution at all pin sites. For the six grade-2 infected pins, loose wires were tensioned, local wound care performed and intravenous antibiotic therapy (dependent on sensitivities) given, with cure in all. Two infected half pins with grade-3 infection were removed and replaced.

Overall, there were 20 complications in 17 patients, a rate of 1.2 per patient. We rated complications as minor

(problem) in ten patients (50%), major (obstacle) in eight (40%) and true (sequelae) in two (10%) (Table II).

Discussion

Many surgical techniques have been described for the treatment of tibial nonunion.¹⁻⁷ These can achieve bony union, but problems such as malalignment, leg-length discrepancy, deformity and infection may not be corrected. Ilizarov⁸ introduced the concept of resection of the site of nonunion and acute shortening combined with bone lengthening by distraction osteogenesis using a circular external frame. This method can maintain or regain limb length and also successfully deal with deformity, infection, joint contracture and malalignment.^{7,9-21} However, there are drawbacks such as the long fixation time and complications related to the docking site including delayed or nonunion, malalignment and infection.

We considered that the strategy described by Cierny et al,²² Mader, Cripps and Calhoun,²⁵ and Tetsworth and Cierny²⁶ was more successful for the treatment of infected nonunion of the tibia than the one-stage operation reported by Ilizarov.²⁷ Therefore our strategy for the 11 infected patients in our series was radical debridement, dead-space management, and reconstruction of the tibia by using distraction osteogenesis. The most important stage is radical debridement of all dead or ischaemic bone and soft tissue, until clean living bone is reached. This appearance is often referred to as the 'paprika' sign.²⁶ The dead space is then managed using antibiotic-impregnated beads. Systemic antibiotics were also administered dependent on culture and sensitivities. After a period of six weeks the final reconstruction stage was undertaken if there were no clinical or laboratory signs of infection based on the level of the ESR and CRP.

Table III. Details of bone-transport studies

Authors	Number of patients	Mean bone loss (cm)	External fixator index (mths/cm)	Complication rate per patient
Atesalp et al ¹⁸	43	9.7	1.4	1.1
Cattaneo et al ¹¹	28	4.0	2.2	0.6
Cierny and Zorn ¹²	21	6.5	2.6	1.4
Dendrinis et al ¹⁵	28	6.0	1.7	2.5
Green et al ¹⁰	17	5.1	1.9	3.5
Marsh et al ¹³	25	4.1	2.1	2.1
Paley and Maar ²¹	19	10.0	1.6	2.9
Polyzois et al ¹⁶	42	6.0	1.6	1.4
Saleh and Rees ¹⁴	8	6.5	2.5	2.2
Song et al ¹⁹	27	8.3	1.0	0.5
Mean	25.8	6.6	1.9	1.8

Table IV. Comparison of bone-transport studies and the present study (mean values)

	Number of patients	Bone loss (cm)	External fixator index (mths/cm)	Complication rate per patient
Bone-transport studies	25.8	6.6	1.9	1.8
Present study (acute shortening and re-lengthening)	17	5.6	1.4	1.2

Soft-tissue loss often complicates the treatment of tibial nonunion with bone loss. Skin grafts, rotation flaps and free flaps have been recommended for tibial nonunion associated with soft-tissue loss.²⁻⁵ Such surgery may require a microvascular team and increase hospitalisation time, cost, and morbidity. By contrast, acute, gradual shortening at the docking site makes wound closure easier and simultaneously compensates for bone loss. In our study, soft-tissue loss in ten patients was successfully treated by acute, gradual shortening at the docking site and no secondary soft-tissue surgery was necessary. However, in the presence of a major bone defect, as occurred in one patient (case 17) and who had bone loss of 10 cm, simple soft-tissue surgery was necessary to treat soft-tissue invagination.

Bone transport is a popular method of treating tibial nonunion with bone loss. Several authors have compared bone transport with other methods of managing post-traumatic tibial bone defects and concluded that the Ilizarov method⁸ was safer, less expensive, faster, and easier to perform.^{10,12,13} Others have also reported very good results with bone transport.^{9,10,12,15-21} However, all these studies reported a long external fixator time and a high rate of complications. In these studies the mean external fixator index was 1.9 months/cm and the mean complication rate per patient was 1.8 (Table III).

Giebel²⁸ was the first to introduce this technique which he called primary shortening. Saleh and Rees¹⁴ reported a study comparing bone transport and bifocal compression time distraction. They concluded that the compression-distraction group had a shorter treatment time and lower rate of complications. Finally, Sen et al²⁹ reported the results of this technique for the treatment of grade-III open tibial fractures with bone and soft-tissue loss. They found the technique to be a safe, reliable, and generally successful

method for the treatment of open tibial fractures with bone and soft-tissue loss.

Our main aim was to decrease the period of external fixation and to diminish the rate of complications. In our study most external fixator index complications (50%; ten patients) were minor and did not require additional surgery. This compares well with bone-transport studies (Table IV). We believe that our lower complication rate may be attributed to fewer problems at the docking site. Bone-transport studies report that most complications were related to the docking site such as nonunion, delayed union, malalignment, low cross-sectional area, and soft-tissue invagination.^{7,9,10,12,21} Many authors suggest that bone grafting should be performed in bone-transport cases because the bone ends lose their viability and potential for union due to atrophy following resection.^{7,10,12-17,20,21} By contrast, acute shortening provides good apposition at the docking site immediately after resection, when the bone ends have maximal viability and potential for union. In our study only four patients required bone grafting after many failed previous operations (a mean of 6.5 operations; 5 to 8). We would recommend bone grafting in such patients as soon as docking position is accomplished.

Other complications such as angulation and translation, low cross-sectional area, and invagination have frequently been reported in bone-transport studies but in our study only one patient (case 17) required secondary surgery and another (case 13) achieved union with recurvatum of 10°. In addition, the bone ends were in contact during both the distraction and consolidation phase of lengthening. Therefore, the external fixation index decreased because the external fixation time was related only to the distraction gap, compared with bone transport studies.

We were able to obtain union, normal alignment, and limb-length equalisation in all patients without the recur-

rence of infection. We achieved excellent results in 16 patients and good in one in terms of bone scores, and excellent results in 15 patients and good in two as regards the functional scores. The external fixator index and complication rate were significantly less compared with those in other bone-transport studies.

The major disadvantage of our study is the small number of patients and there is no direct comparison with any other method of treatment.

We conclude that acute, gradual shortening of bone defects followed by re-lengthening is a safe, viable, and successful method in selected cases of tibial nonunion with bone loss. The technique allows for union, together with realignment, re-orientation, and equalisation of leg length without recurrence of infection. It provides primary wound closure without the requirement for secondary surgery in patients who have soft-tissue loss.

No benefits in any form have been received or will be received from a commercial party related directly or indirectly to the subject of this article.

References

- Papineau LJ, Alfageme A, Dolcourt JP, Pilon L.** Chronic osteomyelitis: open excision and grafting after saucerization. *Int Orthop* 1979;3:165-76 (in French).
- Lowenberg DW, Freibell RJ, Louie KW, Eshima I.** Combined muscle flap and Ilizarov reconstruction for bone and soft tissue defects. *Clin Orthop* 1996;332:37-51.
- Lenoble E, Lewertowski JM, Goutallier D.** Reconstruction of compound tibial and soft tissue loss using a traction histogenesis technique. *J Trauma* 1995;39:356-60.
- Gordon L, Chiu EJ.** Treatment of infected nonunions and segmental defects of the tibia with staged microvascular muscle transplantation and bone grafting. *J Bone Joint Surg [Am]* 1988;70-A:377-86.
- Atkins RM, Madhavan P, Sudhakar J, Whitwell D.** Ipsilateral vascularized fibular transport for massive defects of the tibia. *J Bone Joint Surg [Br]* 1999;81-B:1035-40.
- Tu YK, Yen CY, Yeh WL, et al.** Reconstruction of posttraumatic long bone defect with free vascularized bone graft: good outcome in 48 patients with 6 years follow-up. *Acta Orthop Scand* 2001;72:359-64.
- Aronson J.** Current concepts review: limb lengthening, skeletal reconstruction bone transport with the Ilizarov method. *J Bone Joint Surg [Am]* 1997;79-A:1243-58.
- Ilizarov GA.** Clinical application of tension-stress effect for limb lengthening. *Clin Orthop* 1990;250:8-26.
- Paley D, Catagni MA, Argnani F, et al.** Ilizarov treatment of tibial nonunions with bone loss. *Clin Orthop* 1989;24:146-65.
- Green SA, Jackson MJ, Wall DM, Marinow H, Ishkanian J.** Management of segmental defects by the Ilizarov intercalary bone transport method. *Clin Orthop* 1992;280:136-42.
- Cattaneo R, Catagni M, Johnson EE.** The treatment of infected nonunion and segmental defects of the tibia by the methods of Ilizarov. *Clin Orthop* 1992;280:143-52.
- Cierny G 3rd, Zorn KE.** Segmental tibial defects: comparing conventional and Ilizarov methodologies. *Clin Orthop* 1994;301:118-23.
- Marsh JL, Prokuski L, Biermann JS.** Chronic infected tibial nonunions with bone loss: conventional techniques versus bone transport. *Clin Orthop* 1994;301:139-46.
- Saleh M, Rees A.** Bifocal surgery for deformity and bone loss after lower limb fractures: comparison of bone-transport and compression-distraction methods. *J Bone Joint Surg [Br]* 1995;77-B:429-34.
- Dendrinou GK, Kontos S, Lyritis E.** Use of the Ilizarov technique for treatment of non-union of the tibia associated with infection. *J Bone Joint Surg [Am]* 1995;77-A:835-46.
- Polyzois D, Papachristou G, Katsiopoulos K, Plessas S.** Treatment of tibial and femoral bone loss by distraction osteogenesis: experience in 28 infected and 14 clean cases. *Acta Orthop Scand* 1997;68(Suppl 275):84-8.
- Marsh DR, Shah S, Elliot J, Kurdy N.** The Ilizarov method in nonunion, malunion and infection of fractures. *J Bone Joint Surg [Br]* 1997;79-B:273-9.
- Atesalp AS, Basbozkurt M, Erler E, et al.** Treatment of tibial bone defects with the Ilizarov circular external fixator in high-velocity gunshot wounds. *Int Orthop* 1998;22:343-7.
- Song HR, Chao SH, Koo KH, et al.** Tibial bone defect treated by internal bone transport using the Ilizarov method. *Int Orthop* 1998;22:293-7.
- Cierny G 3rd.** Infected tibial non-unions (1981-1995): the evolution of change. *Clin Orthop* 1999;360:97-105.
- Paley D, Maar DC.** Ilizarov bone transport for tibial defects. *J Orthop Trauma* 2000;14:76-85.
- Cierny G 3rd, Mader JT, Penninck JJ.** A clinical staging system for adult osteomyelitis. *Clin Orthop* 2003;414:7-24.
- Paley D, Herzenberg HE, Tetsworth K, McKie J, Bhava A.** Deformity planning for frontal and sagittal plane corrective osteotomies. *Orthop Clin North Am* 1994;25:425-65.
- Paley D.** Problems, obstacles, and complications of limb lengthening by the Ilizarov technique. *Clin Orthop* 1990;250:81-104.
- Mader JT, Cripps MW, Calhoun JH.** Adult posttraumatic osteomyelitis of the tibia. *Clin Orthop* 1999;360:14-21.
- Tetsworth K, Cierny G 3rd.** Osteomyelitis debridement techniques. *Clin Orthop* 1999;360:87-96.
- Ilizarov GA.** The treatment of pseudoarthroses complicated by osteomyelitis and the elimination of purulent cavities. *Transosseous osteosynthesis*. Heidelberg: Springer-Verlag, 1992:495-543.
- Giebel G.** Primary shortening in soft tissue defects with subsequent callotaxis in the tibia. *Unfallchirurg* 1991;94:401-408.
- Sen C, Kocaoğlu M, Eralp L, Gulsen M, Cinar M.** Bifocal compression-distraction in the acute treatment of grade III open tibia fractures with bone and soft-tissue loss: a report of 24 cases. *J Orthop Trauma* 2004;18:150-7.